

Embryogenic effects of Doxorubicin in chicken embryo

Abbas Razzaq Abed*, Abeer Fadhil Ibraheem and Hassan Adheem Abbas

Technical Institute of Babylon, Al-Furat Al-Awsat Technical University (ATU), Iraq.

ABSTRACT

This study aims to show the effect of Doxorubicin on chicken embryos by injecting this drug into the eggs of chickens containing 10-day-old embryos. One hundred eggs were selected and divided evenly into four groups, each group containing 25 eggs. The first group was considered a control group (normal saline injection), and the 2nd (T1 group), 3rd (T2 group) and 4th (T3 group) were injected with Doxorubicin according to the body surface area of the chicken egg at a dose of 20, 40 and 60 mg/m², respectively. In the current study embryos in Doxorubicin-injected groups showed morphological and histological changes that were directly proportional to the increased dose, including decrease in the body weight and length and histopathological changes in heart and liver tissue compared to control group. Also, a reduction in the hatching rate was observed for Doxorubicin-injected groups (T1, T2 and T3): 0% hatching rate compared to the control group that showed a 100% hatching rate. The doses of Doxorubicin used in this study caused a decrease in the weight and length of chicken embryos and led to the death of all fetuses, as well as caused tissue lesions in the heart and liver.

KEYWORDS: embryogenic, effects, Doxorubicin, chicken embryo.

INTRODUCTION

Cancer is an intractable disease that affects humans and animals and is life threatening. The global

burden of cancer has reached 18.1 million people, and the number of people who died as a result of the disease has reached around 9.6 million in 2018 [1]. The use of various medications to treat cancer, called chemotherapy, prevents the division of cancer cells and prevents them from spreading in the body [2]. Doxorubicin is one of the most common drugs for the treatment of cancers of the prostate, breast, bone marrow, uterus, lymph nodes, bladder and liver [3], and it is an anthracycline antibiotic and is isolated from the *Streptomyces peucetius var. caesius* [4]; anthracycline antibiotics act by preventing DNA replication and leads to inhibition of protein synthesis in the cancer cells of patients [5]. Chemotherapy drugs in general cause several side effects (Hair loss, weakness, lethargy, vomiting and pain) that reflect negatively on the patient's health and interfere with the vital activities of the body, and chemotherapy causes birth defects of the fetus, as a result of cancer treatment in females during pregnancy (Humans and animals), as a result of interference with the cell division of developing fetuses [6]. Because of the danger of this drug to pregnant females and its effects on fetal development, this study aims to demonstrate the effect of Doxorubicin on the morphological and histological development of chicken embryos.

MATERIALS AND METHODS

Doxorubicin

Doxorubicin was purchased from local pharmacies in Baghdad under the commercial name Adrimisin[®] and was manufactured by the Turkish company Saba. Each flacon contained 50 mg of Doxorubicin

*Corresponding author: dr_abas2008@yahoo.com, inb.abs3@atu.edu.iq

hydrochloride in the form of a sterile red powder, which was dissolved in 50 ml of Sodium chloride solution before intravenous infusion.

Preparation of Doxorubicin

Fifty milligrams of Doxorubicin hydrochloride was dissolved by adding Sodium chloride solution to produce a total volume of 50 ml. Each ml of the final solution contained 1 mg of Doxorubicin hydrochloride. To calculate the total dose of Doxorubicin, the length and weight of chicken eggs were measured according to the following law (Mosteller equation):

$$\text{Dose of Doxorubicin (mg)} = \sqrt{(\text{Height [cm]} * \text{Weight [kg]}) / 3600} \times \text{BSA (mg/m}^2)$$

Height means Height of chicken eggs (cm).

Weight means Weight of chicken eggs (Kg).

BSA means Body surface area (mg/m²).

Experiment design

One hundred eggs (The eggs were obtained from a hatchery in Babel governorate/Iraq) containing 10-day-old chicken embryos were selected at a weight of 62-64 gm and a length of 55-57 cm and divided into four groups as shown in Figure 1. Each group containing 25 eggs were injected with Doxorubicin to demonstrate its effect on fetal growth of chicken embryos during the incubation period as follows (All experimental procedures for handling animals and administering the drug were implemented according to the guidelines of the local ethics committee of Iraq medical universities):

Control group (C group): Eggs of this group were injected with 0.75 ml of Sodium chloride solution (0.09% w/v) per egg.

First group (T1 group): Eggs of this group were injected with Doxorubicin hydrochloride solution according to egg body surface area (20 mg/m²).

Second group (T2 group): Eggs of this group were injected with Doxorubicin hydrochloride solution according to egg body surface area (40 mg/m²).

Third group (T3 group): Eggs of this group were injected with Doxorubicin hydrochloride solution according to egg body surface area (60 mg/m²).

Injection into chicken eggs

On the tenth day of life of the embryo inside the egg the embryonic mass and the albumin part were determined by candle light as shown in Figure 2. The top of the egg shell near the airspace was selected and it was sterilized using NaOCl (3% v/v) and the egg was left to dry and then punctured using a nail with a sharp end. Doxorubicin was injected into the egg albumin away from the embryo through the hole that had previously been created on the egg shell, as shown in Figure 3. After the injection was completed, the hole on the surface of the egg shell was closed using wax and the eggs were returned to the incubator until hatching.

Study parameters

1. Body weight change: After the end of the egg incubation period, the weight of the embryos and the chicks of the experimental groups were calculated.
2. Body length change: After the end of the egg incubation period, the lengths of the embryos and the chicks of the experiment groups were calculated by a graduated ruler, and the length was calculated from the top of the head to the end of the tail.
3. Hatching rate (%): The hatching rate was calculated according to the following formula:
Hatching rate (%) = (number of eggs hatched) / total number of eggs for each group) x 100
4. Histopathological examination: The specimens of livers and heart were fixed using 10% neutral buffered formalin solution till the preparation of histological sections. Tissues were embedded in paraffin and several tissue sections were prepared for histological sections then stained with Hematoxylin-Eosin (H and E) dye [7].

Statistical analysis

The results of this study were analyzed by the F-test (One-way ANOVA) at a statistical level of 0.05 by using the statistical program SPSS (Version 13).

RESULTS

The results of the present study showed morphological changes after the end of the




Figure 1. Experimental egg groups included control group (C) and treated groups (T1, T2 and T3 groups) that were injected with 20, 40 and 60 mg/m² Doxorubicin, respectively.




Figure 2. 10-day-old chicken embryo from the incubator. White arrow shows the egg albumin, green arrow shows the yolk sac and the yellow arrow shows the embryonic growth. I = Chicken egg lacks embryonic growth, II = Chicken embryo aged 10 days.

incubation period, which included loss of fluff and growth retardation in chicken embryos resulting from Doxorubicin injection in the eggs (T1, T2 and T3 groups) on the tenth day of incubation compared with the control group (C group) as shown in Figure 4.

The body weight and body length of chicken embryos showed a significant decrease at a




Figure 3. I: 10-day-old chicken embryo from the incubator. Yellow arrow shows the embryonic mass, green arrow shows the egg albumin. II: Doxorubicin injection site in egg shell.

statistically significant level of $p < 0.05$, in groups of chicken eggs injected with Doxorubicin (T1, T2 and T3) compared with the control group, Tables 1 and 2.

Doxorubicin injected in the T1, T2 and T3 groups caused death of all embryos and therefore the hatching rate (%) of eggs after 21 days of artificial incubation was zero percent compared to the control group (C group), as shown in Table 3.

Histopathological sections of the organs of the T1, T2 and T3 groups showed microscopic lesions in

Table 1. Chicken embryo after the end of hatching time.

| Group | Body weight/gm M ± SE |
|-------|---------------------------|
| C | 40.01 ± 0.07 ^A |
| T1 | 5.31 ± 0.11 ^B |
| T2 | 4.04 ± 0.10 ^C |
| T3 | 3.15 ± 0.09 ^D |

LSD = 0.22

Capital letters indicate a significant difference at the level of $p < 0.05$.**Table 2.** Body length change of chicken embryo after 21 days in the incubator.

| Group | Body length/mm M ± SE |
|-------|---------------------------|
| C | 95.80 ± 0.69 ^A |
| T1 | 62.70 ± 0.49 ^B |
| T2 | 60.10 ± 0.48 ^C |
| T3 | 52.60 ± 0.56 ^D |

LSD = 1.34

Capital letters indicate a significant difference at the level of $p < 0.05$.**Table 3.** Hatching ratio (%) of chicken embryo after 21 days in the incubator.

| Group | Hatching ratio (%) |
|-------|--------------------|
| C | 100 |
| T1 | 0 |
| T2 | 0 |
| T3 | 0 |

the tissues and cells of the liver and heart of chicken embryo after the end of the egg incubation. These microscopic lesions increase in dead embryos when the dose of doxorubicin is increased, as shown in Figures 5 and 6.

DISCUSSION

This study showed a decrease in weight and length of chicken embryos (T1, T2 and T3 groups) with low hatching rate after the end of egg incubation compared with the control group. These results were interpreted as follows:

Doxorubicin acts by intercalating into the nuclear material (DNA-Helix) and/or binds covalently to cellular proteins involved in DNA replication and transcription. Such interactions result in inhibition of DNA, RNA, and synthesis of proteins, leading ultimately to cytotoxic effect (cell death) [8, 9].

The genotoxic, cytotoxic and histotoxic effects of Doxorubicin may be the result of free radical formation. There are two ways by which free radicals are formed by Doxorubicin: The first way - Doxorubicin acts on the products of a semi-quinone free radical by the action of Nicotinamide adenine dinucleotide phosphate (NADPH)-dependent reductase enzyme that produces a single electron reduction. In the presence of O_2 , redox cycling of Doxorubicin-derived quinone-semiquinone yields superoxide radicals. The second way - Doxorubicin free radicals come from a non-enzymatic mechanism that involves reactions with iron (Fe^{3+} reacts with Doxorubicin in a redox reaction after which the iron atom accepts an electron and a Fe^{2+} Doxorubicin free radical complex is produced). This iron-Doxorubicin complex can reduce O_2 to H_2O_2 and other active oxygen species [10]. Doxorubicin stimulated the formation of free radicals, and contributed to reduce the mechanism of transfer of albumin to the embryonic fluid, causing a decrease in the volume of amniotic fluid and resulting in the decrease in the body weight and length of growing chicken embryos [11].

Doxorubicin causes increase in tissue Ca^{2+} ion levels, which may contribute to cardiotoxicity (cardiac cell death). The mechanism by which Doxorubicin disturbs tissue Ca^{2+} ion levels may be through interference in various Ca^{2+} ion transport processes (this mechanism acts by inhibiting the translocation of certain Ca^{2+} ions in cardiac cell membranes), and therefore it will have an effect on the action of the Na^+-Ca^{+2} exchanger in cardiac sarcolemma [12] and Ca^{+2} -ATPase activity in the sarcoplasmic reticulum [13]. Also Doxorubicin is characterized by its ability to cause damage to the tissues of the heart (cardiotoxic effects) and liver (hepatotoxic effects) [14, 15], which is consistent with the current study which showed the presence of microscopic tissue and cellular lesions in the heart and liver of chicken embryos, that occurred as a

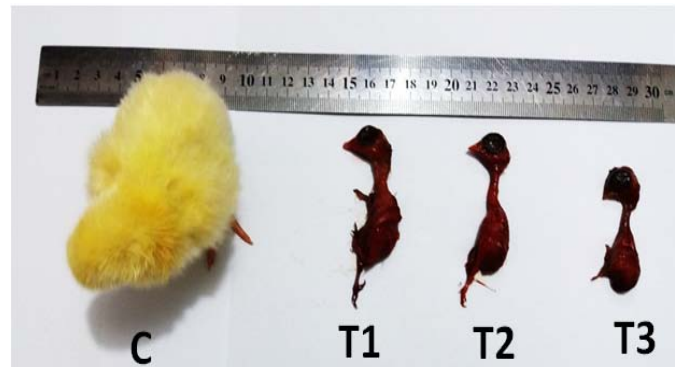

Figure 4. 21-day-old chicken embryos from the incubator. Control group (C) was injected with normal saline and the treated groups (T1, T2 and T3 groups) were injected with 20, 40 and 60 mg/m² Doxorubicin, respectively.

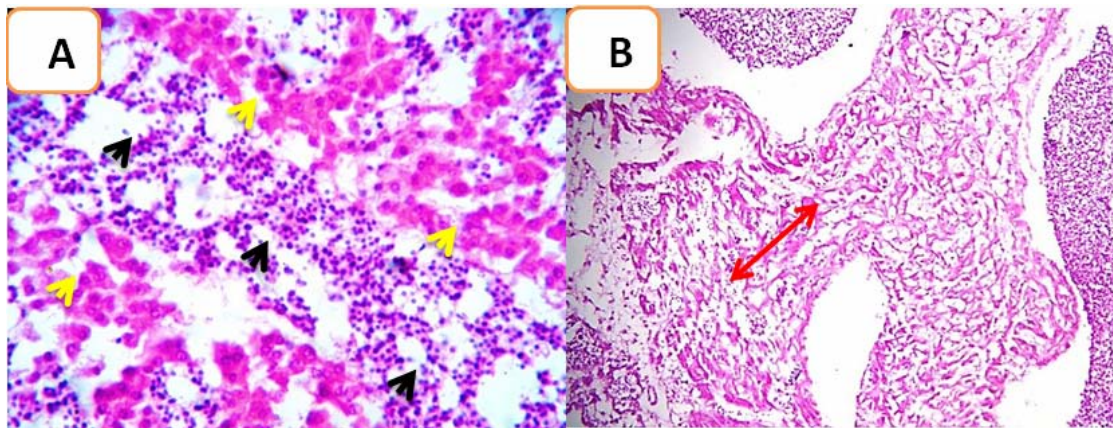


Figure 5. Histopathological section of the liver of a chicken embryo after treatment with Doxorubicin shows moderate to severe depletion of hemopoietic tissue (The black arrow) with disruption of hepatic cords (The red arrow) with no evidence of the megakaryocytic cells. The yellow arrow shows the destruction of both hepatic tissue and hemopoietic tissue with a wide haemorrhagic area that appears more atrophied with higher magnification (H and E stain), X40.

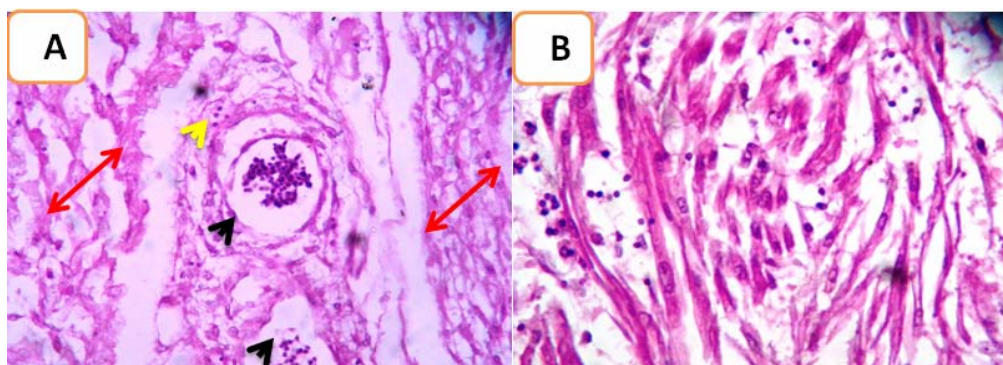


Figure 6. Histopathological section of the heart of a chicken embryo after treatment with Doxorubicin shows fragmentation and separation of muscle bundles (The red arrow) with intramuscular blood vessel congestion and dilation (The black arrow) with scant infiltration of inflammatory cells (The yellow arrow).

result of the production of superoxide radicals which disturbs tissue Ca^{2+} ion levels.

CONCLUSION

The doses of Doxorubicin used in this study caused a decrease in the weight and length of chicken embryos and led to the death of all fetuses, as well as caused tissue lesions in the heart and liver.

ACKNOWLEDGMENTS

The authors are grateful to Mr. Mohammed Jeflawi for providing the necessary facilities to carry out the research.

CONFLICT OF INTEREST STATEMENT

There are no conflicts of interest.

REFERENCES

1. International Agency for Research on Cancer. 2018, 16h00pm Geneva time.
2. Kehe, K. Balszuweit, F. Steinritz, D. and Thiermann, H. 2009, *Toxicology*, 263, 12.
3. Vargas, A., Zeisser-Labouebe, M., Lange, N., Guny, R. and Delie, F. 2007, *Toxicology*, 59, 1162.
4. Lomovskaya, N., Otten, S. L., Doi-Katayama, Y., Fonstein, L., Liu, X. C., Takatsu, T., Inventi-Solari, A., Filippini, S., Torti, F., Colombo, A. L. and Hutchinson, C. R. 1999, *J. Bacteriol.*, 181, 305.
5. Pang, B., Qiao, X., Janssen, L., Velds, A., Groothuis, T., Kerkhoven, R., Nieuwland, M., Ovaa, H., Rottenberg, S., van Tellingen, O., Janssen, J., Huijgens, P., Zwart, W. and Neefjes, J. 2013, *Nature Communications*, 4, 1908.
6. Shahrasbi, A. A., Afshar, M., Shokraneh, F., Monji, F., Noroozi, M., Ebrahimi-Khojin, M., Madani, S. F., Ahadi-Barzoki, M. and Rajabi, M. 2014, *Exper. Clin. Sci. Int. Online J. Adv. Sci.*, 13, 491.
7. Luna, L., Luna, G. L. and Lee, A. A. 1968, *Manual of Histological staining methods of the armed forces*. Institute of pathology, (3rd Ed.), McGraw-Hill Book Company, New York: USA.
8. Cutts, S., Parsons, P., Sturm, R. and Phillips, D. 1996, *J. Biol. Chem.*, 271, 5422.
9. Cutts, S., Swift, L., Rephaeli, A., Nudelman, A. and Phillips, D. 2005, *Curr. Med. Chem. Anti Cancer Agents*, 5, 431.
10. Quiles, J. L., Huertas, J. R., Battino, M., Mataix, J. and Ramirez-Tortosa, M. C. 2002, *Toxicology*, 180, 79.
11. Shingadia, H. U. 2015, *American Journal of Advanced Drug Delivery*, 236, 247.
12. Caroni, P., Villani, F. and Carafoli, E. 1981, *FEBS Lett.*, 3, 184.
13. Olson, R. D., Mushlin, P. S., Brenner, D. E., Fleischer, S., Cusack, B. J., Chang, B. K. and Boucek, R. J. 1988, *Proc. Nati. Acad. Sci. USA*, 85, 3585.
14. Durak, I. Ozturk, H. S., Kavutcu, M., Birey, M., Yel, M., Guven, T., Olcay, E., Kacmaz, M. and Canbolat, O. 1998, *Cancer Res. Ther. Cont.*, 5, 133.
15. Clemmons, D. R. 2007, *Nat. Rev. Drug Discov.*, 6, 821.